INTEGUMENT IN MAMMALS

The integumentary system in mammals is an organ system consisting of skin along with its exocrine glands and its derivatives like hair, nails, claws etc. The skin, only a few millimeters thick, is by far the largest organ in the body. An average person's skin has a surface area of almost 20 square feet. Skin forms the body's outer covering and forms a barrier to protect the body from harmful chemicals, disease, UV light, and physical damage. Hair and nails extend from the skin to reinforce the skin and protect it from environmental damage. The exocrine glands of the integumentary system produce sweat, oil, and wax to cool, protect, and moisturize the skin's surface.

ANATOMY OF INTEGUMENTARY SYSTEM IN MAN

Epidermis

- Epidermis is the most superficial layer of the skin that covers almost the entire body surface.
- It rests upon and protects the deeper and thicker dermis layer of the skin. It is only about 0.1 mm thick but is made of rows of stacked squamous epithelial cells.
- The epidermis is an avascular region of the body as it does not contain any blood vessel. Cells of the epidermis receive all of their nutrients via diffusion of fluids from the dermis.

- ***Cells of epidermis:*** The epidermis is made of several specialized types of cells such as:
  - ✓ **Keratinocytes:** Almost 90% of the epidermis is made of cells known as keratinocytes. Keratinocytes develop from stem cells at the base of the epidermis and begin to produce and store the protein keratin. Keratin makes the keratinocytes very tough, scaly and water-resistant.
  - ✓ **Melanocytes:** At about 8% of epidermal cells, melanocytes form the second most numerous cell type in the epidermis. Melanocytes produce the pigment melanin to protect the skin from ultraviolet radiation and sunburn.
  - ✓ **Langerhans cells:** These are the third most common cells (just over 1% of all epidermal cells). These are star shaped cells dispersed singly throughout the upper part of stratum spinosum. Langerhans cells' role is to detect and fight pathogens that attempt to enter the body through the skin. Thus they are components of cell mediated immunity.
  - ✓ **Merkel cells:** Finally, Merkel cells make up less than 1% of all epidermal cells but have the important function of sensing touch as mechanoreceptors. Merkel cells form a disk along the deepest edge of the epidermis where they connect to nerve endings in the dermis to sense light touch.

- ***Layers of epidermis:*** In most of the body, the epidermis is arranged into 4 distinct layers. In the palmar surface of the hands and plantar surface of the feet, the skin is thicker than in the rest of the body and there is a fifth layer of epidermis.
  - ✓ **Stratum basale or stratum germinativum:** The deepest region of the epidermis is the stratum basale or stratum germinativum, which contains the stem cells that undergo mitotic activity to form all of the other cells of the epidermis. The cells gradually form all other layers of epidermis. The cells of the stratum basale include cuboidal keratinocytes, melanocytes, and Merkel cells.
  - ✓ **Stratum spinosum:** Superficial to stratum basale is the stratum spinosum layer where Langerhans cells are found along with many rows of spiny keratinocytes. The spines found here are cellular projections called desmosomes that form between keratinocytes to hold them together and resist friction.

- ✓ **Stratum granulosum:** Just superficial to the stratum spinosum is the stratum granulosum, where keratinocytes begin to produce waxy lamellar granules to waterproof the skin. The layer is so named because of the granules present in the cell cytoplasm. The keratinocytes in the stratum granulosum are so far removed from the dermis that they begin to die from lack of nutrients.
- ✓ **Stratum lucidum:** In the thick skin of the hands and feet, there is a layer of skin superficial to the stratum granulosum known as the stratum lucidum. It is made of several rows of clear, dead keratinocytes that protect the underlying layers.
- ✓ **Stratum corneum:** The outermost layer of skin is the stratum corneum. The stratum corneum is made of many rows of flattened, dead keratinocytes that protect the underlying layers. Dead keratinocytes are constantly being shed from the surface of the stratum corneum and being replaced by cells arriving from the deeper layers.

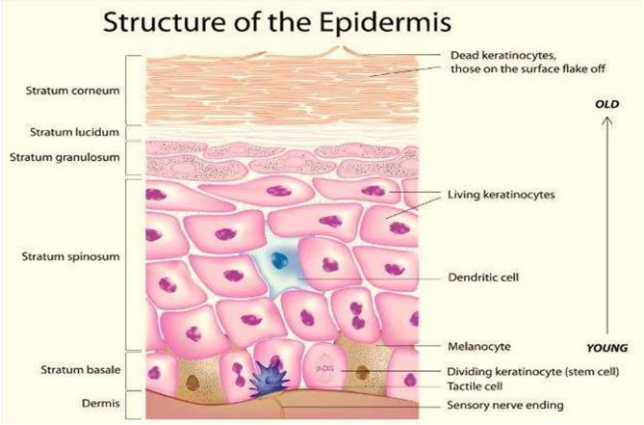

Dermis

- The dermis is the deeper layer of the skin found under the epidermis. It is much thicker than the epidermis and gives the skin its strength and elasticity. Leather is made from dermis.
- It is mostly made of dense irregular connective tissue along with nervous tissue, blood, and blood vessels.
- There occur specialized structures in the dermis such as sweat gland, sebaceous gland, Meissner's corpuscles (touch receptors), Pacinian corpuscles (pressure receptors), heat receptors, sensory nerve endings and vascular plexuses associated with thermoregulation.
- Apart from these, many mammals have scent glands that may be located in anal region (e,g. Weasels), on the face (e.g. bats, antelopes), on the back (e.g. kangaroo rats), on the feet (some artiodactyls) etc. Some of these are derived from sweat glands and some, from sebaceous glands. These glands produce substances with distinct odour that may serve for defense, recognition or sexual attraction.
- Within the dermis there are two distinct regions: the papillary layer and the reticular layer.
- **Papillary layer:** The papillary layer is the superficial layer of the dermis that borders on the epidermis. This layer contains many finger-like extensions called dermal papillae that protrude superficially towards the epidermis. The dermal papillae increase the surface area of the dermis and contain many nerves and blood vessels that are projected toward the surface of the skin. Blood flowing through the dermal papillae provide nutrients and oxygen for the cells of the epidermis. The nerves of the dermal papillae are used to feel touch, pain, and temperature through the cells of the epidermis.
- **Reticular layer:** The deeper layer of the dermis, the reticular layer, is the thicker and tougher part of the dermis. The reticular layer is made of dense irregular connective tissue that contains many tough collagen and stretchy elastin fibres running in all directions to provide strength and elasticity to the skin. The reticular layer also contains blood vessels to support the skin cells and nerve tissue to sense pressure and pain in the skin.

Hypodermis

- Deep to the dermis is a layer of loose connective tissues known as the hypodermis, subcutis, or subcutaneous tissue.
- The hypodermis serves as the flexible connection between the skin and the underlying muscles and bones as well as a fat storage area.
- Areolar connective tissue in the hypodermis contains elastin and collagen fibres loosely arranged to allow the skin to stretch and move independently of its underlying structures.
- Fatty adipose tissue in the hypodermis stores energy in the form of triglycerides. Adipose also helps to insulate the body by trapping body heat produced by the underlying muscles.

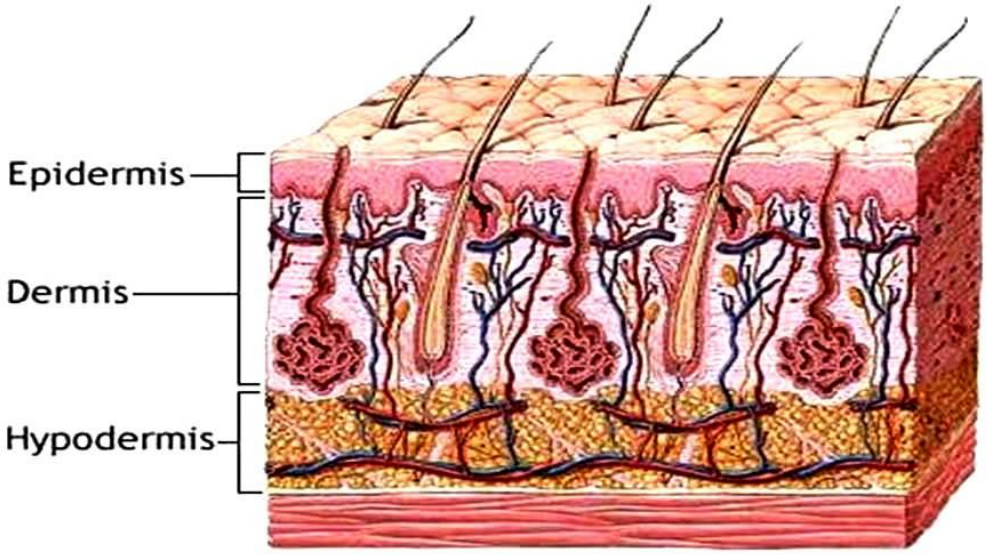

Hair

- Hair is an epidermal derivative of the skin made of columns of tightly packed dead keratinocytes found in most regions of the body.
- The few hairless parts of the body include the palmar surface of the hands, plantar surface of the feet, lips, labia minora, and glans penis.
- The structure of hair can be broken down into three major parts: the follicle, root, and shaft.
- The hair follicle is a depression of epidermal cells deep into the dermis.
- Stem cells in the follicle reproduce to form the keratinocytes that eventually form the hair while melanocytes produce pigment that gives the hair its colour.
- Within the follicle lies the hair root, the portion of the hair below the skin's surface. As the follicle produces new hair, the cells in the root push up to the surface until they exit the skin.
- The hair shaft consists of the part of the hair that is found outside of the skin.
- The hair shaft and root are made of 3 distinct layers of cells: the cuticle, cortex, and medulla.
- The cuticle is the outermost layer made of keratinocytes. The keratinocytes of the cuticle are stacked on top of each other like shingles so that the outer tip of each cell points away from the body.
- Under the cuticle are the cells of the cortex that form the majority of the hair's width. The spindle-shaped and tightly packed cortex cells contain pigments that give the hair its colour.
- The innermost layer of the hair, the medulla, is not present in all hairs. When present, the medulla usually contains highly pigmented cells full of keratin. When the medulla is absent, the cortex continues through the middle of the hair.
- Hair helps to protect the body from UV radiation by preventing sunlight from striking the skin. Hair also insulates the body by trapping warm air around the skin.

Sudoriferous or Sweat Glands

- Sudoriferous glands are exocrine glands found in the dermis of the skin and commonly known as **sweat glands**.
- There are 2 major types of sudoriferous glands: eccrine and apocrine sweat glands.
- Eccrine sweat glands are found in almost every region of the skin and produce a secretion of water and sodium chloride. Eccrine sweat is delivered via a duct to the surface of the skin and is used to lower the body's temperature through evaporative cooling.
- Apocrine sweat glands are found in mainly in the axillary and pubic regions of the body. The ducts of apocrine sweat glands extend into the follicles of hairs so that the sweat produced by these glands exits the body along the surface of the hair shaft. Apocrine sweat glands are inactive until puberty, at which point they produce a thick, oily liquid that is consumed by bacteria living on the skin. The digestion of apocrine sweat by bacteria produces body odour.

Sebaceous Glands

- Sebaceous glands are exocrine glands found in the dermis of the skin that produce an oily secretion known as **sebum**.
- Sebaceous glands are found in every part of the skin except for the thick skin of the palms of the hands and soles of the feet.
- Sebum produced in the sebaceous glands is carried through ducts to the surface of the skin or to hair follicles.
- Sebum acts to waterproof and increase the elasticity of the skin. Sebum also lubricates and protects the cuticles of hairs as they pass through the follicles to the exterior of the body.

Ceruminous Glands

- Ceruminous glands are special exocrine glands found only in the dermis of the ear canals.
- Ceruminous glands produce a waxy secretion known as **cerumen** to protect the ear canals and lubricate the eardrum. Cerumen protects the ears by trapping foreign material such as dust and airborne pathogens that enter the ear canal.
- Cerumen is made continuously and slowly pushes older cerumen outward toward the exterior of the ear canal where it falls out of the ear or is manually removed.

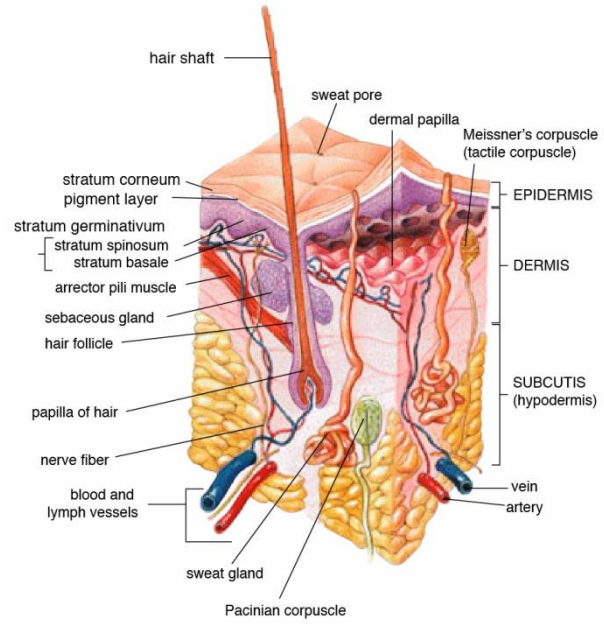

PHYSIOLOGY OF THE INTEGUMENTARY SYSTEM

Keratinization

- Keratinization, also known as cornification, is the process of keratin accumulation within keratinocytes. Keratinocytes begin their life as descendents of the stem cells of the stratum basale. Young keratinocytes have a cuboidal shape and contain almost no keratin protein at all. As the stem cells multiply, they push older keratinocytes towards the surface of the skin and into the superficial layers of the epidermis. By the time keratinocytes reach the stratum spinosum, they have begun to accumulate a significant amount of the protein keratin and have become harder, flatter, and more water resistant. As the keratinocytes reach the stratum granulosum, they have become much flatter and are almost completely filled with keratin. At this point the cells are so far removed from the nutrients that diffuse from the blood vessels in the dermis that the cells go through the process of apoptosis which leavies only a tough, keratin-filled shell behind. Dead keratinocytes moving into the stratum lucidum and stratum corneum are very flat, hard, and tightly packed so as to form a keratin barrier to protect the underlying tissues.

Thermoregulation

- Being the body's outermost organ, the skin is able to regulate body temperature by controlling how the body interacts with its environment. In the case of the body entering a state of hyperthermia, the skin is able to reduce body temperature through sweating and vasodilation. Sweat produced by sudoriferous glands delivers water to the surface of the body where it begins to evaporate. The evaporation of sweat absorbs heat and cools the body's surface. Vasodilation is the process through which smooth muscle lining the blood vessels in the dermis relax and allow more blood to enter the skin. Blood carries heat through the body, pulling heat away from the body organs and depositing it in the skin where it can radiate out of the body and into the external environment.
- In the case of the body entering a state of hypothermia in severe cold, the skin is able to raise body temperature through the contraction of arrector pili muscles and through vasoconstriction. The follicles of hairs have small bundles of smooth muscle attached to their base called arrector pili muscles. The arrector pili form goose bumps by contracting to move the hair follicle and lifting the hair shaft upright from the surface of the skin. This movement results in more air being trapped under the hairs to insulate the surface of the body. Vasoconstriction is the process of smooth muscles in the walls of blood vessels in the dermis contracting to reduce the flood of blood to the skin. Vasoconstriction permits the skin to cool while blood stays in the body's core to maintain heat and circulation in the vital organs.

Vitamin D Synthesis

- Vitamin D, an essential vitamin necessary for the absorption of calcium from food, is produced by ultraviolet (UV) light striking the skin. The stratum basale and stratum spinosum layers of the epidermis contain a sterol molecule known as 7-dehydrocholesterol. When UV light present in sunlight or tanning bed lights strikes the skin, it penetrates through the outer layers of the epidermis and strikes some of the molecules of 7-dehydrocholesterol, converting it into vitamin D_3. Vitamin D_3 is converted in the kidneys into calcitriol, the active form of vitamin D. When our skin is not exposed to sufficient amounts of sunlight, we can develop vitamin D deficiency, potentially leading to serious health concerns.

Protection

- The skin provides protection to its underlying tissues from pathogens, mechanical damage, and UV light.
- Pathogens, such as viruses and bacteria, are unable to enter the body through unbroken skin due to the outermost layers of epidermis containing an unending supply of tough, dead keratinocytes. This protection explains the necessity of cleaning and covering cuts and scrapes with bandages to prevent infection.

- Minor mechanical damage from rough or sharp objects is mostly absorbed by the skin before it can damage the underlying tissues. Epidermal cells reproduce constantly to quickly repair any damage to the skin.
- Melanocytes in the epidermis produce the pigment melanin, which absorbs UV light before it can pass through the skin. UV light can cause cells to become cancerous if not blocked from entering the body.

Skin Colour

- Human skin colour is controlled by the interaction of three pigments: melanin, carotene, and hemoglobin.
- Melanin is a brown or black pigment produced by melanocytes to protect the skin from UV radiation. Melanin gives skin its tan or brown coloration and provides the colour of brown or black hair. Melanin production increases as the skin is exposed to higher levels of UV light resulting in tanning of the skin.
- Carotene is another pigment present in the skin that produces a yellow or orange cast to the skin and is most noticeable in people with low levels of melanin. Haemoglobin is another pigment most noticeable in people with little melanin. Haemoglobin is the red pigment found in red blood cells, but can be seen through the layers of the skin as a light red or pink colour. Haemoglobin is most noticeable in skin coloration during times of vasodilation when the capillaries of the dermis are open to carry more blood to the skin's surface.

Cutaneous Sensation

- The skin allows the body to sense its external environment by picking up signals for touch, pressure, vibration, temperature, and pain.
- Merkel disks in the epidermis connect to nerve cells in the dermis to detect shapes and textures of objects contacting the skin.
- Corpuscles of touch are structures found in the dermal papillae of the dermis that also detect touch by objects contacting the skin. Lamellar corpuscles found deep in the dermis sense pressure and vibration of the skin.
- Throughout the dermis there are many free nerve endings that are simply neurons with their dendrites spread throughout the dermis. Free nerve endings may be sensitive to pain, warmth, or cold. The density of these sensory receptors in the skin varies throughout the body, resulting in some regions of the body being more sensitive to touch, temperature, or pain than other regions.

Excretion

- In addition to secreting sweat to cool the body, eccrine sudoriferous glands of the skin also excrete waste products out of the body.
- Sweat produced by eccrine sudoriferous glands normally contains mostly water with many electrolytes and a few other trace chemicals.
- The most common electrolytes found in sweat are sodium and chloride, but potassium, calcium, and magnesium ions may be excreted as well.
- When these electrolytes reach high levels in the blood, their presence in sweat also increases, helping to reduce their presence within the body. In addition to electrolytes, sweat contains and helps to excrete small amounts of metabolic waste products such as lactic acid, urea, uric acid, and ammonia.
- Finally, eccrine sudoriferous glands can help to excrete alcohol from the body of someone who has been drinking alcoholic beverages. Alcohol causes vasodilation in the dermis, leading to increased perspiration as more blood reaches sweat glands. The alcohol in the blood is absorbed by the cells of the sweat glands, causing it to be excreted along with the other components of sweat.